



A preclinical animal study of a novel, simple, and secure percutaneous vessel occluder for the treatment of varicose veins

Arnold Miller, MD,^a Nir Lilach, IED,^b Raanan Miller, PhD,^a and Lowell Kabnick, MD,^c Cambridge, Mass; Haifa, Israel; and New York, NY

ABSTRACT

Background: Secure, permanent occlusion of the great and small saphenous veins, their tributaries, and perforators is critical for the successful treatment of varicose veins. Current minimally invasive methods replacing surgery are all endoluminal and involve heat (radiofrequency or laser), chemicals (sclerosants and glues), or a combination of mechanical and chemical interventions. This study evaluated in a porcine model the performance of a percutaneous delivery of the Amsel Vessel Occluder (AVO; Amsel Medical Corp, Cambridge, Mass) using ultrasound guidance. The AVO has received United States Food and Drug Administration premarket 510(k) clearance for use in open surgical procedures for tubular structures with diameters of 2 to 7 mm.

Methods: The AVO, a novel mechanical occlusion clip similar to a transfixion suture, is delivered through an 18-gauge hypodermic needle. The AVO is subsequently expanded on either side of the vessel wall, collapsed, and locked together to effect secure vascular occlusion, thus transfixing the targeted vessel. The targeted vessels in five swine (weight >60 kg) under general anesthesia were identified, and the vessel size was measured. Patency of the targeted vessels was confirmed on duplex ultrasound imaging. Each animal provided multiple vessels for percutaneous AVO occlusion. Occlusion was confirmed by duplex ultrasound imaging and by direct examination of the occluded vessel after open surgical exploration.

Results: Thirty vessel occlusions were performed percutaneously, including the common and superficial femoral arteries and veins (n = 24), the carotid artery (n = 4), and the external jugular vein (n = 1) and external jugular vein tributary (n = 1). Measured vessel sizes ranged from 1.8 to 12.7 mm. After vessel transfixion, occlusion was achieved in <30 seconds. A second AVO, if necessary, was delivered to completely occlude the targeted vessel where the vessel was >7 mm diameter (n = 2; external jugular vein, 12.7 mm; carotid artery, 7 mm), or where the initial AVO did not occlude the vessel because of nontransfixion (n = 1). Surgical exposure after occlusion confirmed that all targeted vessels were successfully occluded and demonstrated no evidence of injury to any of the adjacent structures.

Conclusions: This study confirms that the AVO can be effectively delivered percutaneously under ultrasound guidance to occlude blood vessels in the porcine model and may be a useful, time-saving, and cost-effective adjunct to current primary methods of treating reflux in the saphenous veins, their tributaries, or perforators for the treatment of symptomatic varicose veins. (*J Vasc Surg: Venous and Lym Dis* 2017;5:114-20.)

Clinical Relevance: Secure and permanent occlusion of refluxing veins, the saphenous vein, tributaries, and perforators is critical to the successful treatment of symptomatic varicose veins. We describe a novel injectable mechanical occluder, delivered percutaneously through a fine hypodermic needle under ultrasound guidance, which provides secure and permanent occlusion of the targeted veins with elimination of the problems of recanalization associated with current interventional technologies. This may provide a useful, time-saving and cost-effective adjunct to current primary methods for treating primary and recurrent varicose veins.

Varicose veins and their late manifestations are common in adults, increasing in prevalence with increasing age. It is estimated that 23% of United States (U.S.) adults suffer from varicose veins and 6% from

chronic venous disease.¹ They are generally more common in women than men between the ages of 40 and 80 years, although this difference decreases with age. Untreated varicose veins may eventually progress

From the Amsel Medical Corporation, Cambridge^a; the Eliachar Technologies Development, Haifa^b; and the Langone Vein Center, New York University, New York.^c

This work was funded by Amsel Medical Corporation.

Author conflict of interest: A.M., R.M., and L.K. have shares in Amsel Medical Corporation. N.L., consultant engineer, was responsible for the design and development of Amsel Vessel Occluder but does not have shares in Amsel Medical Corporation.

Presented at the Twenty-eighth Annual Meeting of the American Venous Forum, Orlando, Fla, February 24-26, 2016.

Correspondence: Dr Arnold Miller, MD, Amsel Medical Corporation, 171 Hamilton St, Cambridge, MA 02139 (e-mail: arnold@amseltech.com).

The editors and reviewers of this article have no relevant financial relationships to disclose per the Journal policy that requires reviewers to decline review of any manuscript for which they may have a conflict of interest.

2213-333X

Copyright © 2016 by the Society for Vascular Surgery. Published by Elsevier Inc. <http://dx.doi.org/10.1016/j.jvsv.2016.09.001>




Fig 1. The Amsel Vessel Occluder (AVO; Amsel Medical Corp, Cambridge, Mass) and delivery device. **a,** The locked device, a dime, and the 18-gauge delivery needle. **b,** The delivery system shown with the preloaded AVO elements.

to severe chronic venous insufficiency with symptoms and other manifestations, including lower extremity venous ulceration. The related health care costs associated with chronic venous disease approaches \$1 billion annually in the U.S.¹⁻³

Although the pathophysiology of chronic venous disease with lower extremity venous valvular dysfunction has been known since Trendelenburg⁴ described his tests for varicose veins, most of the care is still directed at treating varicose veins only when symptoms or complications occur. The standard of care in the U.S. for the treatment of varicose veins until the turn of the 21st century was surgery with high ligation and stripping of the saphenous vein and phlebectomy of the presenting varicosities. More recently, alternative treatments for varicose veins, including laser or radiofrequency endothermal ablation, together with chemical treatments, sclerosants, and chemical adhesives or a combination of these, have replaced surgery as the standard of care.¹ These procedures have brought the treatment of varicose veins out of the hospital surgical operating rooms and into the outpatient surgical clinics, reducing hospital costs for patient management and minimizing patient morbidity. This migration to an office-based procedure has also altered who performs the procedure.

The underlying pathophysiologic approach to the treatment of these patients has not changed and is aimed at preventing reflux in the lower extremity veins by occluding a long segment of the saphenous vein from the saphenofemoral junction (SFJ) to just below the knee and phlebectomy of the superficial varicosities.

In the early 1990s, Claude Franceschi,⁵ described an alternative saphenous-sparing approach to treat the venous reflux associated with varicose veins.⁶ This approach, CHIVA (Cure conservatrice et Hemodynamique de L'issuifance veineuse en Ambulatoire [conservative hemodynamic cure for varicose veins]), unlike the surgical and endovascular approaches, does not eliminate all reflux saphenous vein but directs the flow of the refluxing blood into the deep veins of the lower extremity to relieve the venous pressure the superficial veins of the extremity and eliminate the clinical

consequences of varicose veins. Because of the combination of demanding ultrasound imaging expertise and the necessary surgical skills required to execute this approach, CHIVA has not been widely adopted, particularly in the U.S.

For both pathophysiologic approaches, secure, permanent occlusion of the targeted veins, which include the saphenous veins, their tributaries, and perforating veins, is critical for the successful treatment of varicose veins and venous insufficiency. This study evaluated the safety and efficacy of a novel mechanical occlusion clip, the Amsel Vessel Occluder (AVO; Amsel Medical Corporation, Cambridge, Mass), delivered percutaneously with ultrasound guidance in the porcine model, which could be used as an alternative or adjunctive treatment method to open surgery or the current vessel occlusion technologies for the treatment of varicose veins.

METHODS

Device description. The occluder elements are preloaded in the 18-gauge needle of the AVO delivery device (Fig 1). The AVO is a mechanical occlusion clip with a length of 7.95 mm after occlusion, that when deployed transfixes the target vessel while clamping it shut. The AVO consists of two star-shaped compression elements and a titanium fine strut that connects and locks the compression elements together. The proximal element, which compresses the near wall of the blood vessel or a tubular structure, and the distal element, which compresses the far wall of the vessel, are made of shape memory metal (nitinol), which once deployed, assumes its designated configuration and closes off the vessel (Fig 2). The individual "arms" of the proximal occlusion component alternate with and interdigitate with the individual arms of the distal occlusion components. These arms are quite flexible and allow for the secure occlusion of vessels of different wall thickness and size and provide a secure sealing zone around the needle entry point (Fig 3).

The AVO clip and delivery device has received U.S. Food and Drug Administration 510(k) clearance, similar to other metal nontransfixing clips (hemoclips), for the

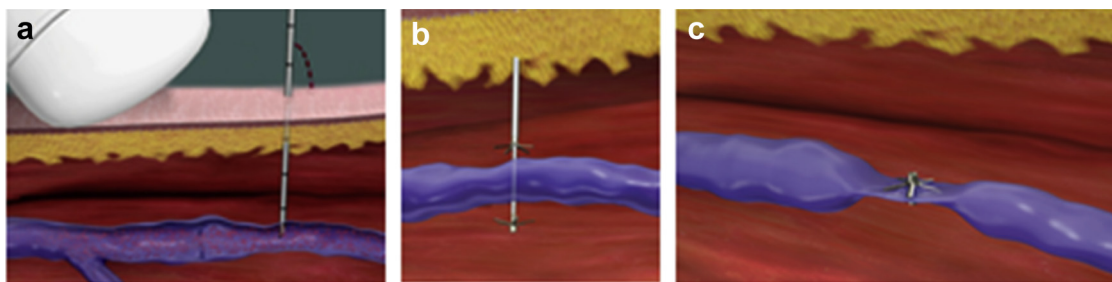


Fig 2. Delivery of the Amsel Vessel Occluder (AVO; Amsel Medical Corp, Cambridge, Mass) under ultrasound guidance. **a**, Confirmation of access to the vessel with the escape of blood through the needle. **b**, Transfixion with delivery of the proximal and distal occluding elements. **c**, Locking together of the occluder elements and disconnection leaves the vessel securely occluded.

occlusion of blood vessels 2 to 7 mm in diameter and for other tubular structures such as the cystic duct or fallopian tube.

Technique. The study was performed at the Lahav Institute of Animal Research, Israel, under the supervision of the veterinary surgeon, the scientific manager at this institute. The studies were approved by the Institute of National Animal Care and Use Committee, Israel.

Five female domestic pigs (*Sus scrofa domestica*), each weighing >60 kg at time of implantation, underwent percutaneous occlusion of 30 selected veins and arteries. Each animal was allowed to acclimate for at least 3 days before surgery. On the day of surgery, food was withdrawn and only water was allowed.

Before occlusion, the selected arteries and veins in the groins and neck were examined with duplex ultrasound imaging. Vessels were selected, measured for size, and patency was confirmed with Doppler ultrasound imaging. Similar to that for any minimally invasive access device, a small incision was made in the skin at the site of needle entry. The ultrasound transducer was held in one

hand and the AVO in the other hand. Under ultrasound guidance, the needle of the device is inserted into the targeted vessel.

A small hole in the needle ~6 cm from the needle tip allows blood to escape, confirming entry into the vessel lumen (Fig 1, a). The pulsatility and color of the bloods helps to distinguish between artery and vein. The needle is passed through the vessel, transfixing the vessel. Once the vessel is transfixied, ultrasound guidance is not essential.

The AVO clip is delivered with four consecutive simple maneuvers on the delivery device: the distal occluding element is delivered, assumes its predetermined configuration, and is gently pulled back onto the vessel, confirmed by a slight resistance. The proximal occluding element is then delivered, and the two elements are locked together. Finally, the locked occluding elements are released, allowing the needle and delivery device to be withdrawn (Fig 1).

Study design. Selected vessels (Table I) were examined with duplex ultrasound imaging, measured, and patency

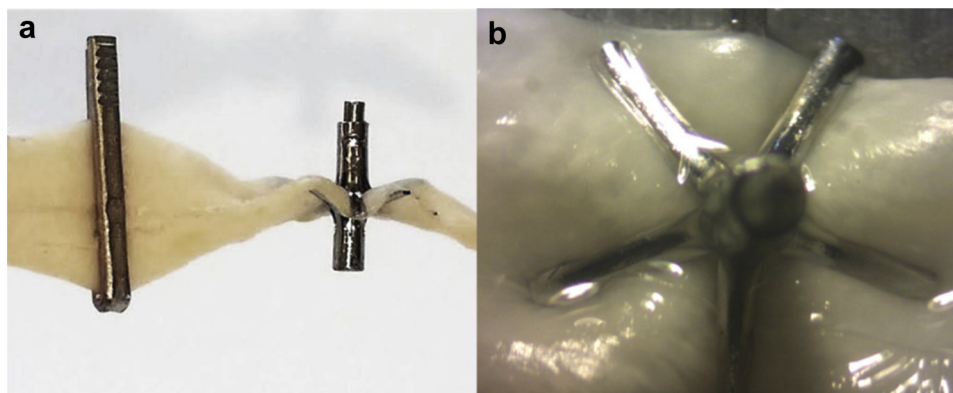


Fig 3. a, Occlusion of simulated 5-mm synthetic saphenous vein (LifeLike; BioTissue, Inc, Doral, Fla) with (left) medium-large Ligacip (Ethicon, Somerville, NJ) and (right) Amsel Vessel Occluder (AVO; Amsel Medical Corp, Cambridge, Mass) showing the different mechanisms of occlusion. The Ligacip occludes by external compression, whereas the AVO transfixes the vessel. **b**, The interweaving and adaptive flexibility of the “arms” creates a sealing zone around the needle transfixion site, which allows for the secure occlusion of vessels of different wall thickness and size.

Table I. Summary of results of 30 percutaneous occlusions

Vessels occluded	Size, mm			AVO clips/occlusion (No.)	Confirmed (US and surgery)
	2-3.5 (No.)	3.6-7 (No.)	>7 (No.)		
Proximal femoral					
Artery	0	10		1	Yes
Vein	0	8		1 (7); 2 ^a (1)	Yes
Distal femoral					
Artery	5			1	Yes
Vein	1			1	Yes
Carotid artery		3	1 (8.3 mm)	1 (2 AVO); 2 (1 AVO)	Yes
External jugular vein				1 (12.5 mm); 2 (12.7 mm)	Yes

AVO, Amsel Vessel Occluder (Amsel Medical Corp, Cambridge, Mass); US, ultrasound.
^aTwo AVO clips were placed (first clip was delivered in muscle).

was confirmed with Doppler flow. Three board-certified interventional radiologists participated in this study. After each percutaneous occlusion, the occluded vessel was examined with duplex imaging to confirm occlusion using standard color-flow Doppler and Doppler waveform. After all of the selected vessels were occluded and the occlusions confirmed by duplex ultrasound imaging, the vessels and the occlusion sites were then surgically exposed ~1 to 2 hours after occlusion in the anesthetized pig before euthanasia and inspected for any bleeding into the surrounding tissues or any injury to the adjacent structures.

The occlusion of the targeted vessel was confirmed by inspection by an independent observer, photographed, and the occluded vessel excised. For arteries, confirmation of the occlusion also included division of the vessel between the percutaneously inserted AVO and a distal hemostat. No bleeding from the divided vessel confirmed competency of the AVO. To ensure that the AVO was effectively occluding the artery and not thrombus, an incision was made in the arterial segment just proximal to the AVO. Pulsatile bleeding from the incised artery confirmed competency of the AVO. This maneuver was not practical in the targeted occluded veins because there were so many collateral tributaries. Occlusion confirmation was confined to in situ inspection and examination of the excised specimen.

The integrity of the AVO clip occlusion with holding pressure measurements (up to >700 mm Hg), the tissue response, and healing of the implanted occluding AVO by inspection and histopathologic examination have been previously documented and reported after surgical vessel occlusion with the AVO.^{7,8}

RESULTS

The AVO was used to occlude 30 vessels percutaneously in five different pigs by three different interventional radiologists. The size of the vessel occluded, the number of clips required for occlusion, and the success

of the occlusion confirmed with duplex ultrasound imaging and surgical exposure are reported in Table I and Table II.

Occlusions were performed in 10 proximal femoral arteries, 8 proximal femoral veins (vessel size range, 3.6-7 mm), 5 distal femoral arteries (superficial femoral arteries), 1 distal superficial femoral vein (vessel size range, 2-3.5 mm; Fig 4); 4 carotid arteries (n = 3: vessel size range, 3.6-7 mm, n = 1: vessel size, 8.3 mm), 1 external jugular vein (vessel size, 12.7 mm), and 1 tributary of the external jugular vein (vessel size, 9.5 mm). All occlusions were achieved with a single AVO (Fig 4), except for the external jugular vein (vessel size, 12.7 mm), in which two clips were required for complete occlusion.

The targeted vessel was not occluded on two occasions with delivery of the first AVO, one because the clip was placed on the edge of the femoral vein and not centrally transfixing the vein, and in the other, the AVO was delivered outside the vessel into the underlying muscle. The interventional radiologist recognized the misplacement and placed a second AVO to occlude the vessel. All other vessels were occluded with a single AVO clip.

In two femoral vein occlusions, where the AVO was not centrally placed, the veins were completely occluded, with no Doppler flow. On surgical exposure, complete vessel occlusion was confirmed. The expanded occlusion elements of the AVO clip, although not centrally placed, had included some surrounding connective tissues to achieve complete occlusion of the vessel (Table II).

Despite the closeness of the femoral vein, artery, and nerve in their tight neurovascular bundle covered by the muscle in the groin of the pig, each targeted vessel was occluded without impinging on the other vessel and or the accompanying nerve and without injury to any of these adjacent structures (Fig 5). These occlusions in the pig are considerably more demanding than in the clinical situation of patients whose veins are targeted for the treatment of their varicose veins.

Table II. Detailed results of 30 percutaneous occlusions by three different interventional radiologists (IR1, IR2, and IR3)

No.	Vessel occluded	Side	Size		Color-flow Doppler		Surgical exposure		Comment
			Mm	Clips, No.	Preocclusion	Postocclusion	Occluded	Injury to adjacent structures	
Pig I (IR3)									
1	Proximal CFA	R	5.3	1	Yes	Yes	Yes	No	
2	Proximal CFV	R	4.6	1	Yes	Yes	Yes	No	AVO not centered but vein completely occluded
3	Proximal CFA	L	4.3	1	Yes	Yes	Yes	No	
4	Proximal CFV	L	5	1	Yes	Yes	Yes	No	
5	Distal FA	R	2.4	1	Yes	Yes	Yes	No	AVO not centered but vein completely occluded
6	Distal FA	L	2.2	1	Yes	Yes	Yes	No	
7	CA	R	4.2	2	Yes	Yes	Yes	No	2 AVOs used to completely occlude
Pig II (IR3)									
1	Proximal CFA	R	5.9	1	Yes	Yes	Yes	No	
2	Proximal FV	R	6.1	2	Yes	Yes	Yes	No	2 AVOs (1 placed into muscle)
3	Proximal CFA	L	5.7	1	Yes	Yes	Yes	No	
4	Distal FA	L	1.8	1	Yes	No	Yes	No	
Pig III (IR3)									
1	Proximal CFA	R	4	1	Yes	Yes	Yes	No	
2	Proximal CFV	L	5.5	1	Yes	Yes	Yes	No	
3	Proximal CFA	L	4.3	1	Yes	Yes	Yes	No	
4	Distal FA	R	2	1	Yes	Yes	Yes	No	
5	Distal FA	L	2.1	1	Y	Yes	Yes	No	
6	CA	R	4.6	1	Yes	Yes	Yes	No	
Pig IV (IR2)									
1	Proximal CFA	R	6.3	1	Yes	Yes	Yes	No	
2	Proximal CFV	R	5.9	1	Yes	Yes	Yes	No	
3	Distal FV	R	3.5	1	Yes	Yes	Yes	No	
4	Proximal CFA	L	6.3	1	Yes	Yes	Yes	No	
5	Proximal CFV	L	6.5	1	Yes	Yes	Yes	No	
6	Tributary of EJV	L	9.5	1	Yes	Yes	Yes	No	
Pig V (IR1)									
1	Proximal CFA	R	6.9	1	Yes	Yes	Yes	No	
2	Proximal CFV	R	6.8	1	Yes	No	No	No	Clip on side of vein only partially occluding vein
3	Proximal CFA	L	<7	1	Yes	Yes	Yes	No	
4	Proximal CFV	L	±7	1	Yes	Yes	Yes	No	Partial occlusion by US; on exposure completely occluded
5	CA	R	±7	2	Yes	Yes	Yes	No	
6	EJV	L	12.7	2	Yes	Yes	Yes	No	
7	CA	L	6.8	1	Yes	Yes	Yes	No	

AVO, Amsel Vessel Occluder (Amsel Medical Corp, Cambridge, Mass); CA, carotid artery; CFA, common femoral artery; EJV, external jugular vein; FA, femoral artery; FV, femoral vein; L, left; R, right; US, ultrasound; V, vein.

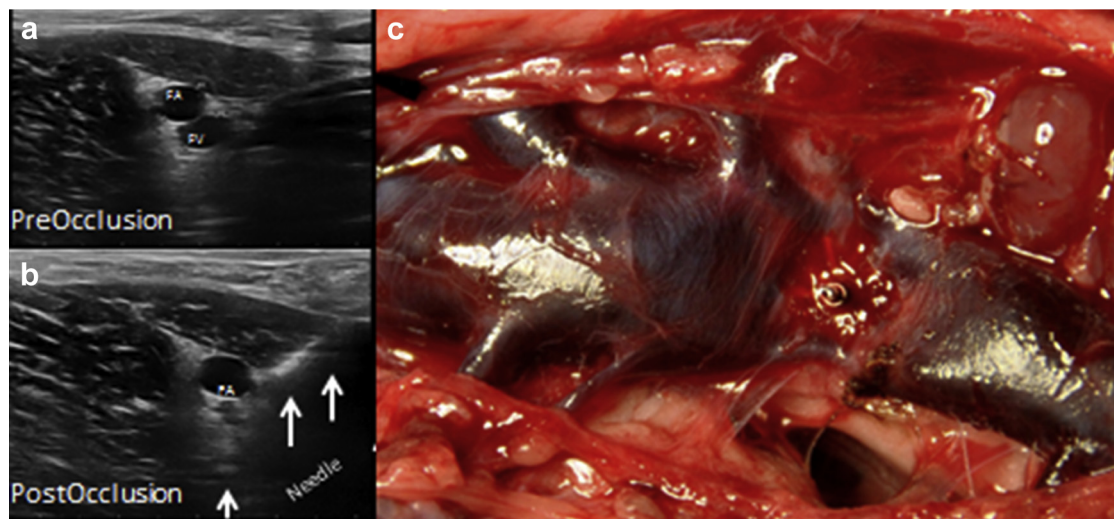


Fig 4. Occlusion of the femoral vein (6.8 mm) in a 60-kg pig. **a**, Preocclusion ultrasound image shows the femoral artery and vein. **b**, Occlusion of the femoral vein with the Amsel Vessel Occluder (AVO; Amsel Medical Corp, Cambridge, Mass; arrows) before detachment from the delivery device. **c**, Surgical exposure confirms occluded femoral vein with distal venous distension. Note the multiple distended tributaries and collapsed proximal vein with a patent tributary.

DISCUSSION

This study represents a first in the ability to occlude blood vessels ranging from 2 to 12.7 mm directly through the skin via a fine hypodermic needle. The novel design of the AVO combines three key characteristics: biplanar clamping, which enables easy and controlled occlusion of blood vessels; transfixion, which provides anchoring similar to a surgically applied transfixion suture that secures the implant in place and eliminates slippage, and grasping with interweaving between occluding arms, which allows occlusion of both arteries and veins of different sizes and wall thickness and ensures an area of hemostasis around the needle entry point (Fig 3).

The AVO and delivery device used in this procedure is of a prototype design that can easily be modified to optimize its performance depending on the circumstance. Although the AVO is only cleared for patient use for vessels between 2 and 7 mm, we have successfully occluded vessels up to 9.5 mm with a single AVO clip (Tables I and II). Larger vessels have been successfully occluded with placement of a second AVO clip. However, the size and length of the occluder used in this study can be easily modified to match the vessel size, such that vessel occlusion can easily be achieved with a single clip.

The technique is simple and similar to other standard percutaneous interventional procedures. Our device involves minimal patient discomfort and recovery, with only a local injection of anesthetic at the site of percutaneous insertion. The entire procedural time is minimal, <30 seconds per occlusion, making such an occlusion method a very cost-effective adjunct to current primary methods of treating reflux in the saphenous veins, their tributaries, or perforators. The three

interventional radiologists participating in this study achieved great success and facility with minimal time spent in familiarizing themselves with the delivery device.

The most important difference compared with the interventional technologies currently in use for treating varicose veins, thermal or chemical endoablation, is the elimination of postocclusion venous recanalization and

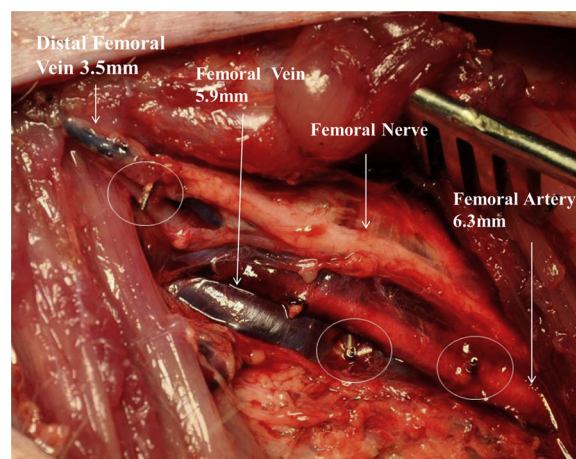


Fig 5. Surgical exposure of the neurovascular bundle in the groin after percutaneous occlusion of the proximal femoral artery (6.3 mm), the proximal femoral vein (5.9 mm), and the distal femoral vein (3.5 mm). Note each vessel was accurately occluded with the Amsel Vessel Occluder (AVO; Amsel Medical Corp, Cambridge, Mass), each separate from each other. The large femoral nerve and adjacent structures were not injured. The white circles surround the occluding AVO.

recurrent reflux. This remains one of the commonest causes of recurrent reflux and varicosities after such treatments.⁹⁻¹¹ Mechanical occlusion with the AVO, similar to a surgical suture ligation, may also eliminate the need for the extensive length of vessel occlusion necessary to prevent recanalization and recurrence of the reflux in the treated vessels. In those cases where the saphenous vein is too large to provide safe laser or radiofrequency endoablation for complete occlusion of the SFJ, occlusion with the AVO may be an alternative to open surgery.

The use of the AVO for perforators could provide a simpler and more permanent solution than current endoablation technologies, where the dangers of leakage into the deep venous system with thrombus propagation and remote embolization are avoided and the results are less than optimal because of a high recurrence rate of perforator patency.⁹⁻¹¹

Use of the AVO for targeted vessel occlusion may facilitate the CHIVA method of treating venous reflux with saphenous vein preservation with elimination of the open surgical ligation procedures, allowing for the entire procedure to be performed percutaneously.¹² With the increasing use of chemical agents for vein ablation, occlusion of the proximal veins, at the SFJ or large tributaries before the intravenous injection of foam sclerosants and glues, may be a simple and safe way to prevent or minimize leakage into the deep venous system, avoiding open surgical ligation and minimizing the potential harmful local and systemic effects of these chemicals.

Finally, with such a simple, minimally invasive, and reliable interventional method to treat venous reflux, the AVO may provide a method to study and evaluate which patients diagnosed with clinically significant reflux and venous insufficiency should undergo early intervention before the onset of the late clinical manifestations of varicose veins to minimize or prevent the cosmetic and debilitating consequences of varicose vein and venous insufficiency and their associated health care costs.

CONCLUSIONS

This study confirms that the AVO can be effectively delivered percutaneously under ultrasound guidance in the porcine model to occlude blood vessels. The AVO provides a mechanical means of permanent, secure vessel occlusion, similar to a transfixion suture, thus eliminating the problem of recanalization that may occur after thermal or chemical vessel occlusion methods. This method of permanent, percutaneous occlusion may be a useful, time-saving, and cost-effective adjunct to current primary methods of treating reflux in the saphenous veins, their tributaries or perforators, for the treatment of symptomatic varicose veins. In addition, the AVO may provide a simple alternative in the event of other treatment method failures (thermal or chemical).

AUTHOR CONTRIBUTIONS

Conception and design: AM, NL, RM, LK
 Analysis and interpretation: AM, NL, RM, LK
 Data collection: AM, NL, RM
 Writing the article: AM, RM
 Critical revision of the article: AM, NL, RM, LK
 Final approval of the article: AM, NL, RM, LK
 Statistical analysis: AM, RM
 Obtained funding: AM, RM
 Overall responsibility: AM

REFERENCES

- Gloviczki P, Comerota AJ, Dalsing MC, Eklof BG, Gillespie DL, Gloviczki ML, et al. The care of patients with varicose veins and associated chronic venous diseases: Clinical practice guidelines of the Society for Vascular Surgery and the American Venous Forum. *J Vasc Surg* 2011;53:2S-48S.
- Smith JJ, Garratt AM, Guest M, Greenhalgh RM, Davies AH. Evaluating and improving health-related quality of life in patients with varicose veins. *J Vasc Surg* 1999;30:710-9.
- Korn P, Patel ST, Heller JA, Deitch JS, Krishnasastri KV, Bush HL, et al. Why insurers should reimburse for compression stockings in patients with chronic venous stasis. *J Vasc Surg* 2002;35:950-7.
- Trendelenburg F. Über die Unterbindung der Vena saphena magna bei Unterschenkelvaricen. *Beitr Klin Chir* 1899;17: 195-210.
- Franceschi C. Theory and practice of the conservative haemodynamic cure of incompetent and varicose veins in ambulatory patients, translated by Evans J. Précy-sous-Thil, France: Editions de l'Armançon; 1988.
- Zamboni P, Escribano JM. Regarding reflux elimination without any ablation or disconnection of the saphenous vein. A haemodynamic model for surgery and durability of reflux-elimination by a minimal invasive CHIVA procedure on patients with varicose veins. A 3-year prospective case study. *Eur J Vasc Endovasc Surg* 2004;28:567-8.
- Miller A, Lilach N, Miller R. A novel secure vessel occluder for minimally invasive and percutaneous treatments. *J Vasc Surg* 2014;59(Suppl 6S):PS234S-89S.
- Miller A, Lilach N, Botero-Anug A, Willenz U, Miller R. A novel secure transfixing blood vessel occluder: comparison with the hemoclip in the porcine model [published online ahead of print October 5, 2016]. *J Surg Res* <http://dx.doi.org/10.1016/j.jss.2016.09.056>.
- O'Donnell TF, Balk EM, Dermody M, Tangney E, Iafrati MD. Recurrence of varicose veins after endovenous ablation of the great saphenous vein in randomized trials. *J Vasc Surg Venous Lymphat Disord* 2016;4:97-105.
- Bush RC, Bush P, Flanagan J, Fritz R, Gueldner T, Koziarski J, et al. Factors associated with recurrence of varicose veins after thermal ablation: results of the recurrent veins after thermal ablation study. *ScientificWorldJournal* 2014;2014: 505843.
- Brake M, Lim CS, Shepherd AC, Shalhoub J, Davies AH. Pathogenesis and etiology of recurrent varicose veins. *J Vasc Surg* 2013;57:860-8.
- Kabick L, Miller A. Ultrasound-placed clips will make CHIVA more widely applicable. In: Greenhalgh RM, editor. *Vascular and endovascular challenges update*. London: BIBA Publishing; 2016. p. 529-34.